

## AN EXPERIMENTAL STUDY OF THE SECONDARY OLFACTORY CONNEXIONS IN *LACERTA VIRIDIS*

By H. J. GAMBLE

*Department of Anatomy, St Mary's Hospital Medical School\**

### INTRODUCTION

The part played by secondary olfactory connexions has long been considered of major importance in the evolution of the vertebrate forebrain. Recent experimental studies of these connexions, e.g. by Clark & Meyer (1947) and by Meyer & Allison (1949) have shown that their distribution is more limited, at least in mammals, than was generally supposed. In particular, it has been shown that few, if any, such fibres end in the septum or hippocampal formation. It was therefore considered to be of importance to re-investigate these connexions in the submammalian forebrain using experimental methods.

*Lacerta viridis* was chosen for these experiments, since specimens were easily obtained, and the normal anatomy of its forebrain has already been described in some detail by Goldby (1934). The method employed has been the examination of the results of the ablation of the olfactory bulbs and other lesions by a silver impregnation method in order to demonstrate axonal and terminal degeneration or the disappearance of fibres. Similar techniques were used very successfully by Armstrong (1950) in an investigation of the optic connexions in *L. vivipara*.

### MATERIALS AND METHODS

Adult specimens of *L. viridis* of both sexes were used. The animals were kept in cages heated to about 30° C., both before and after operation.

#### *Operative techniques*

Under ether anaesthesia the skull was opened with a dental drill and the dura incised. Lesions in the brain were made by cutting with a cystotome. The cavity was filled with penicillin and sulphathiazole crystals, and the skull sealed with solution of Perspex in acetone which dried rapidly to form a very adequate substitute for the bone removed.

The lesions consisted in the removal of the main olfactory bulb either unilaterally or bilaterally, the removal of both the main and the accessory bulbs unilaterally, and division of the habenular commissure by cutting between the hemispheres in the appropriate position. Mortality was low after removal of the olfactory bulb or bulbs (2 in 29) but high where division of the habenular commissure was attempted (3 in 7). When it occurred, death appeared to be due to bleeding into the cranial cavity. Sepsis occurred in two experimental animals but seemed to cause them no

\* This work was begun during the tenure of a post-graduate scholarship from St Mary's Hospital Medical School, and completed with the help of a grant from the Medical Research Council.

inconvenience, being discovered only when the prepared sections were examined; these two brains have been excluded from this study.

The animals were killed by decapitation while under ether anaesthesia, the brains exposed as rapidly as possible and fixed *in situ* for 24 hr. before removal from the skull.

#### *Histological methods*

(i) Four Nissl series were prepared from normal specimens. The brains were fixed in formol-acetic-alcohol; two transverse series were stained with gallocyanin and one horizontal and one sagittal series with cresyl violet. The sections were all cut at  $10\mu$  after paraffin embedding.

(ii) Silver impregnated series were prepared by Nonidez's (1939) technique. All sections were cut at  $5-8\mu$ . The normal material consisted of two transverse and one horizontal series. The experimental material consisted of twenty-seven brains from which satisfactory series were prepared and in which the lesion, survival time, etc. were as follows:

(a) Unilateral removal of the main olfactory bulb; three transverse series with survival times of 2, 10 and 14 days, and ten horizontal series with survival times of 36, 51 and 54 hr. and 3, 4, 5, 7, 10, 11 and 120 days.

(b) Unilateral removal of both main and accessory olfactory bulbs; three transverse series with survival times of 2, 7 and 14 days, and eight horizontal series with survival times of 48, 51, 54 hr. and 3, 4, 5, 9 and 14 days.

(c) Bilateral removal of the main olfactory bulb; one transverse series with survival time of 13 days.

(d) Division of habenular commissure; two transverse series with survival times of 3 and 9 days.

#### OLFACTORY AND RELATED SYSTEMS IN NORMAL MATERIAL

The anatomy of the olfactory and related systems in the forebrain of *L. viridis* has already been described by Goldby (1934) on the basis of normal material. Further examination of similar material has added little to his findings, and it is necessary here to refer only to certain of the fibre tracts which are particularly important for the experimental work to be reported.

In addition to the well-known lateral olfactory tract, intermediate and medial olfactory tracts have also been described. The latter are not well defined nor very clearly separable from each other. They consist of fibres related to the surface of the olfactory tubercle ventrally and the septum medially. Those fibres lying superficially in the olfactory tubercle form the intermediate olfactory tract. They are closely related to the fibres of the forebrain bundles (from which they are not clearly distinguishable) and, medially, are virtually continuous with the ventral part of the medial olfactory tract. This medial olfactory tract can be traced into the dorso-medial and medial parts of the anterior olfactory nucleus, through which the fibres appear to be continued into the septum and the anterior part of the hippocampal cortex. For convenience of description it will be divided into dorsal and ventral parts, although the distinction is not marked by any clear boundary in the normal brain. The dorsal part includes those fibres which appear to pass into the anterior hippocampal cortex; the ventral part passes caudally on the superficial aspect of the

ventral part of the septum and in close association with the intermediate tract. As the fibres of both the intermediate olfactory tract and the ventral part of the medial olfactory tract are followed caudally they become closely related, not only to the fibres of the forebrain bundles but also to 'tuberculo-septal' fibres, the anterior olfacto-habenular tract and, more posteriorly, the diagonal band system. Olfactory tract fibres might contribute to any of these tracts or systems of fibres, but whether they do, and if so, to what extent, cannot be determined from normal material.

The term 'diagonal band' is applied to fibres which cross the base of the hemisphere obliquely on its ventral surface immediately behind the olfactory tubercle. They may be seen in all planes of section but most clearly in horizontal sections which cut the region tangentially (Pl. 2, figs. 8-10). They are so named from an apparent similarity to a band of fibres in this situation described by Broca (1879) in mammals. On the medial side, they may be traced dorsally through the nucleus of the diagonal band and, perhaps after a relay, to the superficial aspect of the hippocampal cortex; in this medial part of their course they are sometimes referred to as the 'olfactory radiations of Zuckerkandl'. Laterally they may be traced into the superficial part of the amygdaloid complex where they are accompanied by fibres of the more deeply situated amygdalo-pre-optic tract (Goldby, 1934), and the superficially placed lateral cortico-habenular tract, from which they are practically indistinguishable. Some fibres of the diagonal band system may enter the stria medullaris lateralis and reach the habenular region. In their course medio-laterally on the base of the brain they are closely related to the pre-optic and supra-optic nuclei with which they may also be connected.

A compact bundle readily identified in the septum (Pl. 1, fig. 1) is the anterior olfacto-habenular tract (Goldby, 1934, and others). It is described as beginning in the dorsal part of the anterior olfactory nucleus whence it can be followed caudally and ventrally through the septum to pass through the diagonal band to the stria medullaris lateralis and the habenular region. Despite its name, its precise origin and termination and the direction in which it conducts are unknown. Together with the amygdalo-pre-optic connexion referred to above, it might well be included in the diagonal band system, and it is clear that a satisfactory analysis of the fibres which cross the ventral surface of the hemisphere in the region of the diagonal band cannot be made in normal material.

The stria medullaris is a bundle of fibres lying along the dorso-medial border of the thalamus, closely related to the habenular nuclei and contributing many fibres to the habenular commissure. In *L. viridis* it may be divided into medial and lateral parts.

The medial part is formed from the medial cortico- and olfacto-habenular tracts. The former is said to derive crossed and uncrossed fibres from the hippocampal cortex, the latter to be connected with the hypothalamic and pre-optic region (Goldby, 1934). This description is tentative since the direction of conduction in these fibres is not known.

The lateral part, the 'stria medullaris lateralis', is of greater interest from the point of view of this investigation. It appears to receive fibres from the amygdaloid region and pyriform cortex through the lateral cortico-habenular tract and also the

fibres already referred to as the anterior olfacto-habenular tract. A third component, the lateral olfacto-habenular tract, is described as joining it from the pre-optic region. The stria medullaris lateralis passes dorsally from the caudal end of the base of the hemisphere lateral to the lateral forebrain bundle, and in the angle between this bundle and the anterior margin of the optic tract (Pl. 2, fig. 7). Dorsal to the forebrain bundles it joins the medial part of the stria medullaris to turn caudally and run back to the habenular commissure. It is clear that the very close relation between the origin of the stria medullaris lateralis and the diagonal band system would make an extensive connexion between the two possible, although contributions to the stria medullaris from the anterior olfacto-habenular tract and the lateral cortico-habenular tract only have so far been described.

#### THE NATURE OF DEGENERATIVE CHANGES IN THE OLFACTORY SYSTEM OF *LACERTA VIRIDIS*

In *L. vivipara*, Armstrong (1950) found that the maximal changes in optic tract fibres were present about 14 days after the optic nerve had been cut. These changes took the form of irregular varicosities along the whole length of the fibres and of rings and solid bulbs on what were taken to be their endings. In the olfactory system of *L. viridis* few, if any, changes of this kind were seen in animals killed more than 3 days after operation. The only change found consistently in all specimens killed at such times was a loss of fibres from situations which varied according to the nature of the lesion. Sometimes some yellowish debris was found in a region from which fibres had disappeared, but this was not constant nor conspicuous enough to serve as a useful criterion of degeneration. The disappearance of fibres is apparently complete at a very early stage. After removal of the main or of the main and accessory olfactory bulbs, the loss of fibres was obvious in animals killed 3 days after the operation. In specimens killed after 5 days the loss was perhaps slightly more marked, but no evidence for any further loss could be found in specimens killed after longer intervals.

In all, ten animals were killed between 36 and 72 hr. after operations on the main or main and accessory olfactory bulbs and examined for evidence of axonal or terminal degeneration. In four of these (36, 51 and two 72 hr. specimens) the results were negative, although in the 72 hr. specimens many fibres had undoubtedly been lost. In two, 48 and 54 hr. specimens respectively, axonal changes in the form of irregular varicosities were present in the olfactory tracts; in the former, end bulbs and rings appeared also to be present over the olfactory tubercle (Pl. 3, figs. 12, 13 and 15) and pyriform cortex. The remaining four specimens showed only scanty evidence of axonal changes, and in no case throughout all the systems which were thought likely to be affected. Fusiform swellings along the course of fibres or, more commonly, near or at their apparent terminations again formed the principal evidence. The anatomical localization of these changes will be described in a later section. Here only their general nature and the question of their reliability as evidence will be considered.

An observation of the loss of fibres was taken as satisfactory evidence that the fibres in question had been cut by the lesion, or their cells of origin removed, provided that it could be made consistently in all other specimens with similar

lesions. The ease with which a loss of fibres can be seen naturally varies with its degree. Where it occurs consistently and completely in a compact and virtually homogenous tract, no difficulty arises; if, however, the loss occurs in a compound fibre system and is incomplete, its recognition may be much more difficult, and the loss of only a few fibres can pass unnoticed. Nevertheless, a thinning out of fibres can be satisfactory evidence when observed unequivocally in a number of specimens all with similar lesions and if carefully controlled by comparison with normal specimens. It is clear, of course, that such observations can give no information about the actual termination of fibres.

In these experiments the evidence obtained from the positive observation of degenerative changes in axons or their endings was, by itself, inadequate for comprehensive anatomical interpretation. The changes were variable and inconstant in their appearance in different specimens. That they were artefacts due to fixation, or some other technical factor, may be excluded, since they were never seen in normal specimens nor in any of the specimens killed more than 3 days after operation (except that a very few such changes were sometimes seen up to 5 days after operation). Moreover, the situations in which they were found, though not usually so widespread as would have been expected, were always regions in which olfactory tract fibres appeared to be present in normal preparations or from which fibres had disappeared in specimens kept for a longer time after removal of the olfactory bulb. One may conclude that although axonal and probably terminal degenerative changes occur after injury to fibres of the olfactory system, they are demonstrable only for a short time during the first 3 days. The variability, even in animals killed at this particular time, probably means that degenerative changes do not become demonstrable at the same moment in all the fibres affected by the lesion. At any one time only a few fibres may be in a condition in which the changes can be demonstrated, at least by the Nonidez technique, and they do not appear to remain in this condition for long. It is also probable that degeneration does not proceed at exactly the same rate in different specimens.

For these reasons, the anatomical findings to be reported are based primarily on the observation of a loss of fibres 3 or more days after removal of the olfactory bulbs, or other lesion, while the degeneration of axons (and possibly terminals) in specimens killed after shorter intervals has provided useful confirmatory evidence. As already indicated the findings in the latter, though less complete, were in no case inconsistent with the findings in the specimens kept for longer periods.

#### EXPERIMENTAL RESULTS

Some of the observations made after removal of the main or of the main and accessory olfactory bulbs merely confirm what was already reasonably well established on the basis of previous work, chiefly in normal material, and these can be dealt with briefly.

Removal of the main bulb (nine specimens) led, after 3 or more days, to a substantial but incomplete loss of fibres from the olfactory peduncle, and a similar loss from among the cells in the dorso-lateral part of the anterior olfactory nucleus. Behind this nucleus the lateral olfactory tract showed a slight thinning of its fibres, but only in the anterior part of its course where it runs on the surface of the brain

along the lower border of the pyriform cortical area. Posteriorly, where it dips beneath the surface into the amygdaloid complex, no difference from the normal side could be seen. There was also some loss of fibres from the superficial aspect of the anterior part of the pyriform cortex.

When, in addition to the main bulb, the accessory bulb was removed (seven specimens) and the animal allowed to survive 3 days or more, the results, so far as the above structures are concerned, were very similar though more marked. There was complete loss of fibres in the stump of the olfactory peduncle and the loss of fibres in the lateral olfactory tract, though still incomplete, could be followed throughout its length into the amygdaloid complex, including the hypopallium posterior.

The observations based on the unilateral removal of both main and accessory bulbs received some confirmation from two specimens killed less than 3 days after operation. In one (L.V. 52, 48 hr. survival), varicosities, some of them vesicular, were seen on nerve fibres throughout the superficial parts of the anterior olfactory nucleus, over the anterior half of two-thirds of the pyriform cortex, throughout the length of the lateral olfactory tract, in the hypopallium posterior and over the surface of the olfactory tubercle (Pl. 3, figs. 12, 13 and 15). In another (L.V. 69, 54 hr. survival) larger varicosities were present throughout the length of the lateral olfactory tract and in the medial olfactory tract (Pl. 3, fig. 14), but not over the pyriform cortex. In two further specimens (L.V. 62 and 70) killed 51 and 54 hr. respectively after removal of the main bulb only, the results, so far as the anterior olfactory nucleus, pyriform cortex and lateral olfactory tract were concerned, were entirely negative.

One may base the following conclusions on these experiments. The fibres in the peduncle are wholly efferent from the olfactory bulbs, and many of them pass no farther than the anterior olfactory nucleus. A proportion of fibres from the main bulb pass without relay into the lateral olfactory tract and probably end in the anterior part of the pyriform cortex; none, or very few, reach the amygdala. Fibres from the accessory bulb, however, pass without relay through the lateral olfactory tract as far as the amygdaloid complex, although it is not possible to say that all do so. Some may end in other regions, e.g. in the pyriform cortex, but there is no evidence for or against this possibility. It is also possible, of course, that fibres from the main bulb influence the amygdala through the lateral olfactory tract after relay in the anterior olfactory nucleus.

In addition, a loss of fibres superficial to the olfactory tubercle occurred in all the series where bulbar ablation was carried out 3 or more days before the animal was killed. In one with a survival period of 54 hr. (L.V. 69) large axonal varicosities were seen in the ventral part of the medial olfactory tract (Pl. 3, fig. 14) and all over the surface of the olfactory tubercle, and in one with a survival time of 48 hr. (L.V. 52) small, solid and vesicular structures were found throughout the superficial part of the tubercle (Pl. 3, figs. 12, 13 and 15). These findings confirm the commonly held view that secondary olfactory fibres end over the surface of the olfactory tubercle.

Certain negative results may also be reported briefly. None of the specimens showed any change whatever in the fibres among the cells of the septal nuclei nor in

fibres related to the hippocampal and dorsal cortical areas. If these structures receive any direct bulbar connexions they must consist of very few fibres indeed, and the fibres which appear to reach them from the dorsal part of the medial olfactory tract probably arise in the anterior olfactory nucleus. Furthermore, bulbar ablations, whether affecting the main bulb only or both main and accessory bulbs, led to no detectable evidence of degeneration in any component of the anterior commissure either as a loss of fibres or as degenerative axonal changes.

The effects of removal of the olfactory bulbs on the ventral part of the medial olfactory tract were more striking and extended more widely than was expected, and must be described at greater length. They were produced by removal of the main bulb only, and were not increased when the accessory bulb was removed as well, so that all the fibres to be considered must originate in the main bulb. One specimen (L.V. 34) in which one main olfactory bulb was removed 3 days before the animal was killed may be taken as typical. The silver impregnation was particularly good and, in spite of the short survival time, the fibre loss was quite definite.

On the side of the operation there was an obvious disappearance of fibres from the region of the ventral part or the medial olfactory tract along the ventro-medial border of the hemisphere. This was continuous caudally with a considerable and unexpected loss of fibres from the diagonal band system caudal to the olfactory tubercle (Pl. 2, fig. 10).

Equally unexpected and more striking was the virtually complete disappearance of the anterior olfacto-habenular tract from the opposite (unoperated) hemisphere (Pl. 2, fig. 9). This, as has been mentioned, is a small but well-defined and particularly compact tract, especially about the middle part of its course, where it lies superficially in the septum (Pl. 1, figs. 1-4).

Careful examination of the stria medullaris lateralis (through which the fibres of the anterior olfacto-habenular tract have been said to run to the habenula) showed, on the unoperated side, a very marked but not quite complete loss of fibres from a small area situated caudally in the bundle adjacent to the anterior margin of the optic tract (Pl. 2, fig. 5). On the operated side this area was occupied by apparently normal fibres which filled the concavity of a crescentic area from which fibre loss was very marked but, again, not complete (Pl. 2, fig. 6). In other words, the appearance in the stria medullaris lateralis on the right and left sides was such that one appeared as the reverse or 'negative' of the other (Pl. 2, figs. 5, 6) and both differed from the normal (Pl. 2, fig. 7).

A very similar difference between the two sides was seen in horizontal sections cutting the diagonal band tangentially on the ventral aspect of the hemisphere (Pl. 2, figs. 9, 10). In fig. 10, the operated side, the anterior olfacto-habenular tract can be seen as a compact, deeply impregnated bundle of fibres postero-medial to the main part of the diagonal band in which fibres are fewer than normal. The corresponding region on the unoperated side (fig. 9) is almost free of fibres, while on this side the main part of the diagonal band contains its normal complement.

The appearances described were seen throughout the stria medullaris lateralis, though with rather more difficulty in the posterior part of its course where it runs along the dorso-medial border of the thalamus. In the habenular commissure an appearance in which bundles of fibres were seen to interdigitate with strips from

which fibre loss was almost complete, replaced the normal uniform appearance of closely packed fibres. In no case was any loss of fibres seen in the plexus surrounding the cells of the habenular nuclei.

It is clear that these regions in which a loss of fibres was observed form a continuous tract passing caudally as the ventral part of the medial olfactory tract to the diagonal band and stria medullaris lateralis on one side, across in the habenular commissure, and then rostrally on the opposite side in the stria medullaris lateralis and anterior olfacto-habenular tract; and that the fibres which disappear are secondary olfactory fibres from the main olfactory bulb which end at or near the anterior extremity of the so-called anterior olfacto-habenular tract of the opposite side, that is, in the dorsal part of the anterior olfactory nucleus and perhaps in adjacent parts of the cortex.

The evidence for the existence of such a long and circuitous crossed secondary olfactory tract, not previously described, needs careful scrutiny. If the findings in L.V. 34 are to be accepted at their face value there does not appear to be any other interpretation than the one which has been given; but conclusions based on observations of a relative or even a complete loss of fibres are always open to the criticism that the apparent loss may be the results of a fortuitous deficiency in the silver impregnation in certain situations. Two things, however, seem to make this criticism inapplicable.

First, although the impregnation in the quite large number of specimens prepared varied somewhat, the variations did not take the form of patchy deficiencies scattered widely in the forebrain. Where the impregnation was deficient a whole region was affected, and all the fibres in it; this defect was most common in the extreme anterior end of the hemisphere, affecting the olfactory peduncle and the anterior olfactory nucleus but did not affect the regions in which the diagonal band and stria medullaris are situated.

Secondly, it was found that the observations which have been described for L.V. 34 could be made in all the specimens which had been subjected to a similar operation. Sixteen specimens were prepared in which the main or main and accessory olfactory bulbs were removed unilaterally and in which the survival time was 3 days or longer. In all of these, the absence of the anterior olfacto-habenular tract on the unoperated side was unequivocal; and in all the tract was present on the operated side. Sometimes a little yellowish debris was found in the position of the tract on the unoperated side (e.g. in L.V. 34) but, in all, the contrast with the normal tract was definite. It may be pointed out that the position of these tracts in the septum is such as to make the comparison of the two sides particularly easy, and that they were clearly present bilaterally in three normal specimens, and in three others, not referred to elsewhere in this paper, with lesions which did not affect the olfactory bulbs or tracts. The loss of fibres from the region of the diagonal band was almost equally clear, especially in the horizontal series. In the stria medullaris lateralis the changes observed are not quite so striking. In the specimen chosen to illustrate these changes the impregnation was good and the fibres well defined against a clear background; some other specimens gave equally clear results, and in the remainder careful examination always established that similar changes had occurred. With the ventral part of the medial olfactory tract the position was somewhat similar, but here the area of the loss of fibres was less clearly defined



owing to intermingling with adjacent fibres, e.g. of the medial forebrain bundle. Nevertheless, the loss of fibres was consistently observed, although more obvious in some specimens than in others. In the habenular commissure excessive impregnation rendered the recognition of areas of fibre loss impossible in two series, but in the others it was observed consistently and took the form already described in L.V. 34.

Attempts were made to obtain further evidence from the presence of degenerative changes in axons at short periods after operation. Eight animals were killed at intervals varying between 36 and 54 hr. after unilateral bulbar ablation. In one of these (L.V. 69), killed 54 hr. after operation, large axonal varicosities were found in the olfactory tracts; those in the ventral part of the medial olfactory tract (Pl. 3, fig. 14) could be traced through the diagonal band and the stria medullaris to the habenular commissure and then forward through the opposite stria into the anterior olfacto-habenular tract. In three others, killed at or about 48 hr. after operation, varicosities were present on the axons of the opposite anterior olfacto-habenular tract near its termination in the dorsal part of the anterior pole of the opposite hemisphere but not elsewhere. The other four specimens gave negative results as far as this system is concerned, and it seems reasonable to assume that this was due either to a failure in the technique or to the absence of a sufficient number of fibres with demonstrable changes at the particular time when the animal was killed. It may be added that in none of these short-term specimens was any evidence of degenerative change seen within the habenular nuclei.

While giving support to the conclusions based on observations of the disappearance of fibres, the number of specimens showing positive degenerative changes was not large, and the following additional tests were carried out.

In one specimen, the main olfactory bulbs were removed bilaterally. After a survival period of 13 days it was found that there was a complete and unequivocal disappearance of the anterior olfacto-habenular tract on both sides. This series was cut transversely and the loss was particularly obvious in the septal region where the tract is compact and isolated from other fibre systems. The ventral part of the medial olfactory tract had also disappeared bilaterally, while the region of the diagonal band caudal to the olfactory tubercle was very conspicuously poor in fibres, the caudal continuation of the ventral part of the medial olfactory tract and the closely related anterior olfacto-habenular tract having disappeared from this situation. The so-called diagonal band now consisted only of fibres in the medial and ventro-lateral walls of the hemisphere, separated from one another ventrally by an area virtually free of fibres. The stria medullaris lateralis consisted only of a few fibres set in a pale-staining matrix, and its appearance throughout resembled that seen only in localized parts after unilateral bulbar ablation. In the habenular commissure the loss of fibres, as compared with the normal, was most striking.

In two specimens the habenular commissure was divided successfully. In one (L.V. 60), 9 days survival, the sections showed that the commissure had been divided completely, and that the knife had passed laterally into the thalamus between the nucleus rotundus and the lateral geniculate body, also damaging the stria medullaris on that side. So far as could be seen, no damage had been caused to the nucleus rotundus itself nor to the lateral forebrain bundle. There was a little damage

to the hippocampal cortex of one hemisphere, and some loss of the underlying alveus fibres was observed. Apart from these direct effects of the lesion the only change seen in the hemispheres was the complete bilateral absence of the anterior olfacto-habenular tract, while fibre loss had occurred bilaterally in a localized area within the stria medullaris lateralis, corresponding to that area from which fibres were lost on the unoperated side after unilateral bulbar ablation. In the second specimen (L.V. 47), survival period 3 days, the lesion appeared to be limited to the habenular commissure and the posterior commissure immediately behind it. Large axonal varicosities were found bilaterally in the stria medullaris lateralis and in the whole extent of the anterior olfacto-habenular tract affecting the majority, if not all, of its fibres (Pl. 3, fig. 11). Smaller varicosities were also seen bilaterally in the lateral cortico-habenular tract, though affecting a smaller proportion of its fibres; no other changes were observed within the hemispheres.

These two experiments were successful within their limits, in that they demonstrate that the fibres of the anterior olfacto-habenular tract conduct rostrally and not caudally as had been thought and as their name implies, and also that they cross in the habenular commissure. They cannot, of course, confirm the bulbar origin of these fibres, but taken with the results of the bulbar ablation experiments they leave little doubt of the existence of a crossing system of secondary olfactory fibres which, having crossed, form the anterior olfacto-habenular tract.

The fibres of the diagonal band, where they are found in the posterior part of the septum in close relation to the nucleus of the diagonal band, were not affected by any of the operations performed. The elimination of the crossing secondary olfactory fibres from the caudal end of the base of the hemisphere after unilateral or, better, bilateral bulbar ablation made the investigation of these fibres much easier and at the same time widely interrupted the apparent continuity of the whole system between medial and lateral centres of the hemisphere. As the fibres in the septum are traced ventrally it can be seen that they do not pass laterally across the base of the hemisphere behind the olfactory tubercle; they pass to the region of the supra-optic nucleus where they appear to end. Virtually all the fibres running obliquely across the base of the hemisphere caudal to the olfactory tubercle, i.e. in the most ventral part of the 'diagonal band', are secondary olfactory fibres—the crossed fibres of the anterior olfacto-habenular tract medially and the uncrossed fibres of the ventral part of the medial olfactory tract on their lateral aspect.

The fact that the medial fibres of the diagonal band end in or near the supra-optic nucleus can be confirmed by an examination of normal material, but is by no means as clear as when the secondary olfactory fibres are eliminated.

#### DISCUSSION

As already stated, the conclusions which concern the lateral olfactory tract differ only slightly from those reached in earlier accounts. Goldby's (1937) observations in Marchi material indicated that secondary olfactory fibres from the main bulb ended in the anterior olfactory nucleus, and it appears from the present work that some also reach the anterior parts of the pyriform cortex. Structures possibly representing degenerating terminals were found in one experimental series relevant to this question. None was seen in actual contact with the body of a cell, so the

relationship may be predominantly axo-dendritic rather than axo-somatic, but the evidence is inadequate for a more definite statement.

The intermediate olfactory tract appears to originate largely in the main olfactory bulb, but the termination of its fibres over the olfactory tubercle had already been inferred from normal material and confirmed experimentally (Goldby, 1937). The condition in mammals is similar, since degeneration has also been found in the lateral and ventral parts of the olfactory tubercle in the rabbit (Clark & Meyer, 1947) and in the anterior and lateral parts of the tubercle in the monkey (Meyer & Allison, 1949) after bulbar ablation.

The dorsal part of the medial olfactory tract has been shown to originate at least mainly in the accessory bulb and to have a less extensive distribution than usually supposed. No evidence was found that any of these fibres reach the septum and the hippocampal formation. They appear to end in the dorsal and medial parts of the anterior olfactory nucleus. At the same time it is impossible to deny that a few may reach the extreme anterior and least differentiated part of the hippocampal cortex where it blends with the anterior olfactory nucleus. This lack of any substantial secondary olfactory connexion with the hippocampal formation is in accord with the experimental findings of Clark & Meyer in the rabbit and with those of Meyer & Allison in the monkey.

Bulbar ablation caused no loss or degeneration of fibres in the 'olfactory component' or indeed in any part of the anterior commissure or in the opposite olfactory bulbs; Goldby (1934) was of the opinion that at least the majority of fibres in the 'olfactory component' of the anterior commissure arose in the anterior olfactory nucleus and adjacent structures. These findings in *L. viridis* differ from those of Clark & Meyer in the rabbit where, after bulbar ablation, degeneration was observed in the anterior commissure, in the opposite olfactory bulb and in the bed nucleus of the opposite stria terminalis and central amygdaloid nucleus. It is true that the degeneration was found to be more extensive when the lesion involved the anterior olfactory nucleus, but fibres of bulbar origin were believed to cross in the anterior commissure.

The most surprising findings are those interpreted as demonstrating the presence of an olfactory tract which takes a circuitous route through the habenular commissure to end near the anterior pole of the opposite hemisphere. The different parts of this tract have all been described in normal material, but never as a continuous system of fibres. Various names have been applied to these parts, that of one, the anterior olfacto-habenular tract, being based on its presumed connexions, those of others, e.g. the stria medullaris lateralis and diagonal band, simply defining their topographical position. Although in themselves non-committal, these latter terms have often, as a result of usage, come to imply specific connexions, e.g. the diagonal band, which is generally understood to consist of fibres linking lateral olfactory centres with the septum and hippocampal formation.

It is clear, therefore, that if the conditions found in *L. viridis* are generally present in other reptiles, a radical revision of terminology is desirable. This is particularly obvious in the case of the anterior olfacto-habenular tract, which, of course, becomes a secondary olfactory tract running rostrally after crossing in the habenular commissure; it is doubtful if it has any functional connexion with the

habenular nuclei, either through axonal or collateral endings. It is hardly less obvious in the case of the 'diagonal band', which needs some further discussion since its presumed connexions, linking medial and lateral olfactory centres, have been used by Johnston (1915) as a basis for theoretical conclusions concerning the evolution of the temporal pole and the general pallium.

In *L. viridis* and probably in other reptiles, fibres in the position of the diagonal band and connecting medial with lateral centres in the hemisphere, if present at all, are extremely few. Most, if not all, of the fibres which cross the base of the hemisphere obliquely behind the olfactory tubercle belong to the secondary olfactory system which has been described, some passing caudally, others rostrally. The medial part of the diagonal band system, described as ascending in the septum to the hippocampal cortex, and closely related to the nucleus of the diagonal band, does not cross the base of the hemisphere and, therefore, does not reach the lateral olfactory centres. In specimens in which removal of the olfactory bulbs resulted in the disappearance of the secondary olfactory fibres, it may be seen that these fibres end in or very close to the supra-optic nucleus. It appears that the nucleus of the diagonal band should be associated with the supra-optic nucleus rather than with the olfactory system and that the alternative name of these fibres, the 'olfactory radiations of Zuckerkandl', is also unsatisfactory. At the lateral end of the diagonal band system fibres also persist after bulbar ablations. Again, in such specimens, it is easy to see that these fibres are not continuous across the base of the hemisphere with those in the septum. They originate or end laterally and appear to join the stria medullaris lateralis, probably representing the lateral cortico-habenular tract described by previous authors. In brief, what has been described as the diagonal band in *L. viridis* should be split into three independent parts, namely:

(1) Fibres situated medially among the cells of the nucleus of the diagonal band and extending dorsally to the hippocampal cortex and ventrally to the region of the supra-optic nucleus.

(2) Fibres lying ventrally behind the olfactory tubercle and forming crossed and uncrossed parts of a secondary olfactory system.

(3) Fibres lying laterally over the surface of the amygdala and probably forming the lateral cortico-habenular tract.

A study of the published descriptions of the reptilian forebrain does not show anything which is necessarily inconsistent with the suggestion that a crossed secondary olfactory tract, similar to the one found in *L. viridis*, is present in other species. There is very little which would justify a more positive statement. In *Cistudo* Johnston (1915) described fibres of the medial olfactory tract as passing caudally to join his 'diagonal band', and Crosby (1917), in the alligator, found similar fibres which passed caudally into close relation with the nucleus of the diagonal band. In *Tupinambis nigropunctatus* Curwen (1937) has described a tractus olfacto-hypothalamicus superficialis, which in her figures occupies a position very similar to the ventral part of the medial olfactory tract in *Lacerta*. She describes it as passing caudally and laterally in close association with the anterior olfacto-habenular tract, and states that it joins the stria medullaris and that some of its fibres may reach the habenular nuclei; most, she thinks, join the medial forebrain bundle from the stria medullaris. Curwen states that this tract arises in the superficial part of the

olfactory tubercle; since her material consisted of a single transverse series stained by the Weigert method, one cannot feel that the evidence for this is adequate, and the fact that the fibres could be traced to the stria medullaris along a course practically identical with that of the ventral part of the medial olfactory tract in *Lacerta* suggests strongly that they belong to the same tract. There are, however, other differences in her description, such as the large contribution from the stria medullaris to the medial forebrain bundle, and in the absence of further evidence, preferably from experimental material, one can say no more than that Curwen's findings in *Tupinambis* suggest strongly a close resemblance to the arrangement of the olfactory tracts found in *Lacerta*, and establish a case for further investigation. It may be added that she also describes an anterior olfacto-habenular tract which agrees in all essential particulars with other descriptions in normal material (e.g. Goldby, 1984), and also sends some of its fibres into the habenular commissure. The corresponding tract described by de Lange (1911) as 'the olfacto-habenular tract' was thought to cross completely in this commissure.

While observations such as these suggest that the condition found in *Lacerta* may well be general throughout Reptilia, it must also be admitted that a continuous bundle of fibres passing back as part of the medial olfactory tract to enter the stria medullaris and cross in the habenular commissure to form the 'anterior olfacto-habenular' tract of the opposite hemisphere, has never previously been described. From the nature of this bundle it is extremely unlikely that any but experimental methods will reveal its presence, and until these methods have been applied more extensively in studies of the reptilian brain, it would be premature to suggest altering a well-established terminology.

A wider survey of the literature of the vertebrate forebrain shows that tracts, which might form part of a similar bundle of secondary olfactory fibres, exist in other orders. In Amphibia, the ventral division of the anterior olfacto-habenular tract (Herrick, 1921, 1933, 1948) or the 'radix olfactorius medialis' of Snessarew (1908) is practically identical with the anterior olfacto-habenular tract described in reptiles. There is no suggestion in the published accounts, however, that it might be a crossed secondary olfactory tract. An interbulbar connexion, crossing in the habenular commissure, has been described e.g. in the frog by Snessarew (1908), in anurans by Röthig (1926) and in *Salamandra* by Kreht (1930). These fibres, however, pass caudally in a dorso-lateral olfactory tract, which appears to be equivalent, in part, to the dorsal division of Herrick's anterior olfacto-habenular tract and quite different in its course from the anterior olfacto-habenular tract of reptiles. According to Herrick, they arise very largely in the anterior olfactory nucleus. Apart, therefore, from the fact that certain authors have described secondary fibres as crossing in the habenular commissure of various amphibians, and the striking similarity between the anterior olfacto-habenular tract of *L. viridis* and the ventral division of anterior olfacto-habenular tract of amphibians (Herrick), no similarity to the lacertilian condition has been found. All these descriptions of the amphibian forebrain have been based on normal material and it seems possible that an experimental investigation might show a condition similar to or identical with that described in *L. viridis*; but at present this cannot be assumed.

So far as mammals are concerned, no reference has been found to any direct

connexion from the olfactory bulb to the diagonal band or stria medullaris. The only suggestion of any resemblance to the condition in *L. viridis* as regards a crossed system of secondary olfactory fibres is found in Loo's (1931) account of the forebrain of the opossum. He described a component of the stria terminalis (stria terminalis 5) which joins the stria medullaris, and observed that its course and relations closely resembled those of the ventral division of Herrick's (1927) anterior olfacto-habenular tract, which is certainly comparable in its course to the anterior olfacto-habenular tract of *L. viridis*. Johnston (1923) identified this tract (Loo's stria terminalis 5) in the opossum and in the rabbit, but it must also be said that none of the more recent experimental studies in mammals has provided any evidence that these fibres are of bulbar origin.

In view of the very incomplete nature of the evidence, it is impossible to draw any general conclusions from this survey with confidence. It may be, since a component of secondary olfactory fibres has been found in the stria medullaris and habenular commissure in several amphibians but not in mammals, that modern reptiles present an elaboration of a fundamentally amphibian condition. The mammals may have arisen independently from generalized amphibian ancestors, and evolved along quite different lines, as suggested by Armstrong (1950) on the basis of his study of the optic system. So far as the olfactory system is concerned, this can be no more than a reasonable speculation, which must await further investigations before much weight can be given to it.

Finally, this work again emphasizes the importance of the experimental analysis of fibre systems, not only in mammalian but also in more primitive vertebrate brains. In addition, it demonstrates some of the limitations and difficulties of the particular method employed. It appears that different fibre systems react very differently to injury so far as concerns the rate of degeneration and the duration of the period during which degenerative changes in axons are demonstrable. It is probable that individual fibres in an apparently homogenous system do not all react at exactly the same time; and there may well be important differences between species in this respect. It follows that it is impossible to generalize from a set of observations which is limited to a single system and a single species; e.g., previous work (Goldby, 1937; Armstrong, 1950) suggested that both myelin sheath and axonal changes would occur more slowly in reptiles than in mammals. This does not appear to be generally so, since many secondary olfactory fibres disappear extremely quickly and, indeed, more quickly than those in the rabbit (Clark & Meyer, 1947).

The short duration of demonstrable changes and the variations in the time after the injury at which they appear make 'false negative' observations a very real possibility. The demonstration of degenerative changes or of fibre loss, if carefully controlled by comparison with normal material, should form a reliable basis on which to form conclusions. An apparent absence of any change may indicate only that too few fibres have disappeared, or show demonstrable changes, to be noticeable; or that the particular specimen has been prepared before the time when changes of a demonstrable kind occur. For this reason the reported observation that no degenerative changes or fibre loss were seen in the hippocampal cortex, septum and habenular nuclei cannot be taken as establishing more than a *prima*

*facie* case that they receive no secondary olfactory fibres. If these structures do receive such fibres, it is probable that they are few in number, but even so it does not necessarily follow that they are, on that account, functionally insignificant.

One may conclude that, in using techniques which rely on the demonstration of axonal degeneration, it is necessary to investigate carefully the nature and time relationship of these changes, not only for a particular species but also for the particular system of fibres which is under investigation; and that this must be done before the observation of the presence or absence of these changes can be used as a reliable basis for anatomical interpretation.

#### SUMMARY

The connexions of the olfactory bulbs in *Lacerta viridis* have been investigated by studying the degenerative changes which occur after removal of the olfactory bulbs and other lesions. Nonidez's silver impregnation technique was used.

Degenerative changes were found to be of the same general type as in other similar investigations, but to occur more quickly than usual, viz. during the first 3 days after operation. In specimens killed after longer intervals the affected fibres had disappeared completely.

Observations, primarily of a loss of fibres following bulbar ablation, led to the following conclusions:

(a) The lateral olfactory tract receives fibres from both main and accessory olfactory bulbs; those from the main bulb end in the anterior olfactory nucleus and the most anterior part of the pyriform cortex; those from the accessory bulb pass to the anterior half to two-thirds of the pyriform cortex and to the amygdaloid nuclei.

(b) The intermediate olfactory tract arises from the main olfactory bulb and its fibres end over the surface of the olfactory tubercle.

(c) The medial olfactory tract can be divided into dorsal and ventral parts.

The dorsal part arises mainly in the accessory olfactory bulb and ends in the anterior olfactory nucleus. No evidence was found that any fibres of bulbar origin end in the septum or hippocampal cortex.

The ventral part runs caudally to reach the region of the diagonal band behind the olfactory tubercle. It passes laterally in the diagonal band and can be traced through the stria medullaris lateralis to the habenular commissure. After crossing in the commissure the fibres continue forwards in the stria medullaris of the opposite hemisphere to become the tract which in previous descriptions has been called the anterior olfacto-habenular tract. This tract is therefore a crossed secondary olfactory tract which runs rostrally to end in or near the anterior olfactory nucleus. This crossed tract originates in the main olfactory bulb.

(d) The diagonal band in *L. viridis* consists largely of the secondary olfactory fibres just described; it contains few if any fibres which connect medial and lateral centres in the hemisphere.

It is concluded that a crossed secondary olfactory tract, similar to that demonstrated in *L. viridis*, may be present in reptiles generally and possibly in Amphibia, but that further experimental work is necessary before this conclusion can be made definite.

This work has been carried out under the direction of Prof. F. Goldby of the Department of Anatomy, St Mary's Hospital Medical School. I wish to express my thanks to him and to Mr J. A. Armstrong for advice and criticism which they have given throughout.

REFERENCES

- ARMSTRONG, J. A. (1950). An experimental study of the visual pathways in a reptile (*Lacerta vivipara*). *J. Anat., Lond.*, **84**, 146-167.
- BROCA, P. (1879). Localisations Cerebrales: Recherches sur les centres olfactifs. *Rev. Anthropol. Ser. II*, **2**, 385-455.
- CAIRNEY, J. (1926). A general survey of the forebrain of *Sphenodon punctatum*. *J. comp. Neurol.* **42**, 255-348.
- CLARK, W. E. LE GROS & MEYER, M. (1947). The terminal connexions of the olfactory tract in the rabbit. *Brain*, **70**, 304-328.
- CROSBY, E. C. (1917). The forebrain of *Alligator mississippiensis*. *J. comp. Neurol.* **27**, 325-402.
- CURWEN, A. O. (1937). The telencephalon of *Tupinambis nigropunctatus*. I. Medial and cortical areas. *J. comp. Neurol.* **66**, 375-404.
- GOLDBY, F. (1934). The cerebral hemispheres of *Lacerta viridis*. *J. Anat., Lond.*, **68**, 157-215.
- GOLDBY, F. (1937). An experimental investigation of the cerebral hemispheres of *Lacerta viridis*. *J. Anat., Lond.*, **71**, 332-355.
- HERRICK, C. J. (1921). The connections of the vomero-nasal nerve, accessory olfactory bulb and amygdala in Amphibia. *J. comp. Neurol.* **33**, 213-280.
- HERRICK, C. J. (1927). The amphibian forebrain. IV. The cerebral hemispheres of *Amblystoma*. *J. comp. Neurol.* **43**, 231-325.
- HERRICK, C. J. (1933). The amphibian forebrain. VI. *Necturus*. *J. comp. Neurol.* **58**, 1-288.
- HERRICK, C. J. (1948). *The Brain of the Tiger Salamander*. University of Chicago Press.
- JOHNSTON, J. B. (1915). Cell masses in the forebrain of the turtle, *Cistudo carolina*. *J. comp. Neurol.* **25**, 393-468.
- JOHNSTON, J. B. (1923). Further contributions to the study of the evolution of the forebrain. *J. comp. Neurol.* **35**, 337-481.
- KREHT, H. (1930). Ueber die Faserzüge im Zentralnervensystem von *Salamandra maculosa* L. *Z. mikr. anat. Forsch.* **23**, 239-320.
- LANGE, S. J. DE (1911). Das Vorderhirn der Reptilien. *Folia Neuro-biol., Lpz.*, **5**, 548-597.
- LOO, Y. T. (1931). The forebrain of the opossum, *Didelphis virginiana*. *J. comp. Neurol.* **52**, 1-148.
- MEYER, M. & ALLISON, A. C. (1949). An experimental investigation of the connexions of the olfactory tracts in the monkey. *J. Neurol. Neurosurg. Psychiat.* **12**, 274-286.
- NONIDEZ, J. F. (1939). Quoted by Lillie, R. D. (1948). *Histopathologic Technic*. Philadelphia: Blakiston Co.
- RÖTHIG, P. (1926). Beiträge zum Studium des Zentralnervensystems der Wirbeltiere. 10. Ueber die Faserzüge im Vorder- und Zwischenhirn der Anuren. *Z. mikr. anat. Forsch.* **5**, 23-56.
- SNESAREW, P. (1908). Ueber die Nervenfasern des Rhinencephalons beim Frosche. *J. Psychol. Neurol., Lpz.*, **13**, 97-125.

EXPLANATION OF PLATES

All figures are photographs of sections of the brain of *Lacerta viridis* prepared by Nonidez's silver impregnation method.

PLATE I

(Magnification in figs. 1 to 4, × 80.)

- Fig. 1. Transverse section through the septal region of a normal brain to show the anterior olfacto-habenular tract present bilaterally.
- Fig. 2. Transverse section through the same region 7 days after unilateral bulbar ablation. The anterior olfacto-habenular tract is present only on the side from which the olfactory bulb was removed.
- Fig. 3. Transverse section through the diagonal band region to show the anterior olfacto-habenular tract present bilaterally in the normal brain.
- Fig. 4. Transverse section through the same region 7 days after unilateral bulbar ablation (the same specimen as in fig. 2). The anterior olfacto-habenular tract is present only on the operated side.



## PLATE 2

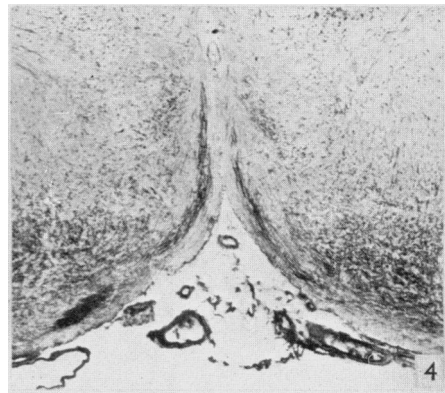
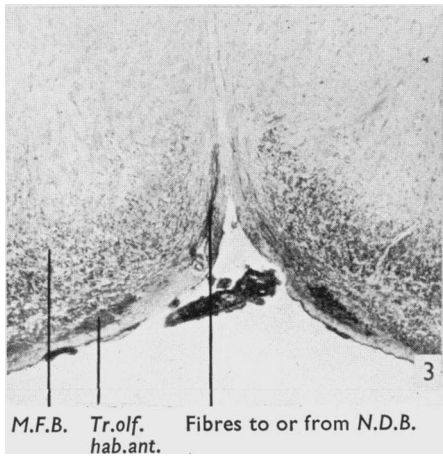
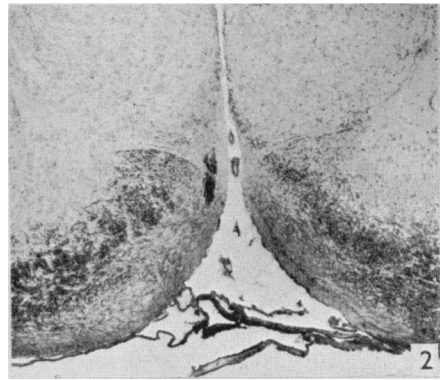
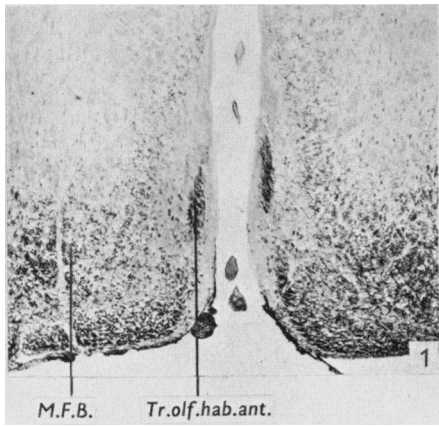
- Fig. 5. Horizontal section passing through the stria medullaris lateralis of the unoperated side 3 days after unilateral bulbar ablation. ( $\times 150$ .) A small area of fibre loss is seen in contact with the anterior margin of the optic tract. Compare with figs. 6 and 7.
- Fig. 6. Horizontal section passing through the same region of the operated side in the same specimen as in fig. 5. ( $\times 150$ .) A crescentic area of fibre loss is seen separated from the anterior margin of the optic tract by a small bundle of fibres. Compare with figs. 5 and 7.
- Fig. 7. Horizontal section passing through the region illustrated in figs. 5 and 6, but in a normal brain. ( $\times 150$ .) Compare with figs. 5 and 6.
- Fig. 8. Horizontal section cutting the diagonal band region tangentially in a normal brain. ( $\times 100$ .)
- Fig. 9. Horizontal section, similar to fig. 8, on the unoperated side 3 days after unilateral bulbar ablation (the same specimen as in figs. 5 and 6). ( $\times 100$ .) The section shows a loss of fibres from the medial and posterior part of the diagonal band system (the anterior olfacto-habenular tract); the remaining fibres are chiefly those of the medial olfactory tract (ventral part).
- Fig. 10. The corresponding section to the one illustrated in fig. 9, but from the operated side. ( $\times 100$ .) The presence of an intact anterior olfacto-habenular tract contrasts strongly with its absence on the opposite side (fig. 9). Loss of fibres from the medial olfactory tract, ventral part, though definite, is less pronounced than in most specimens.

## PLATE 3

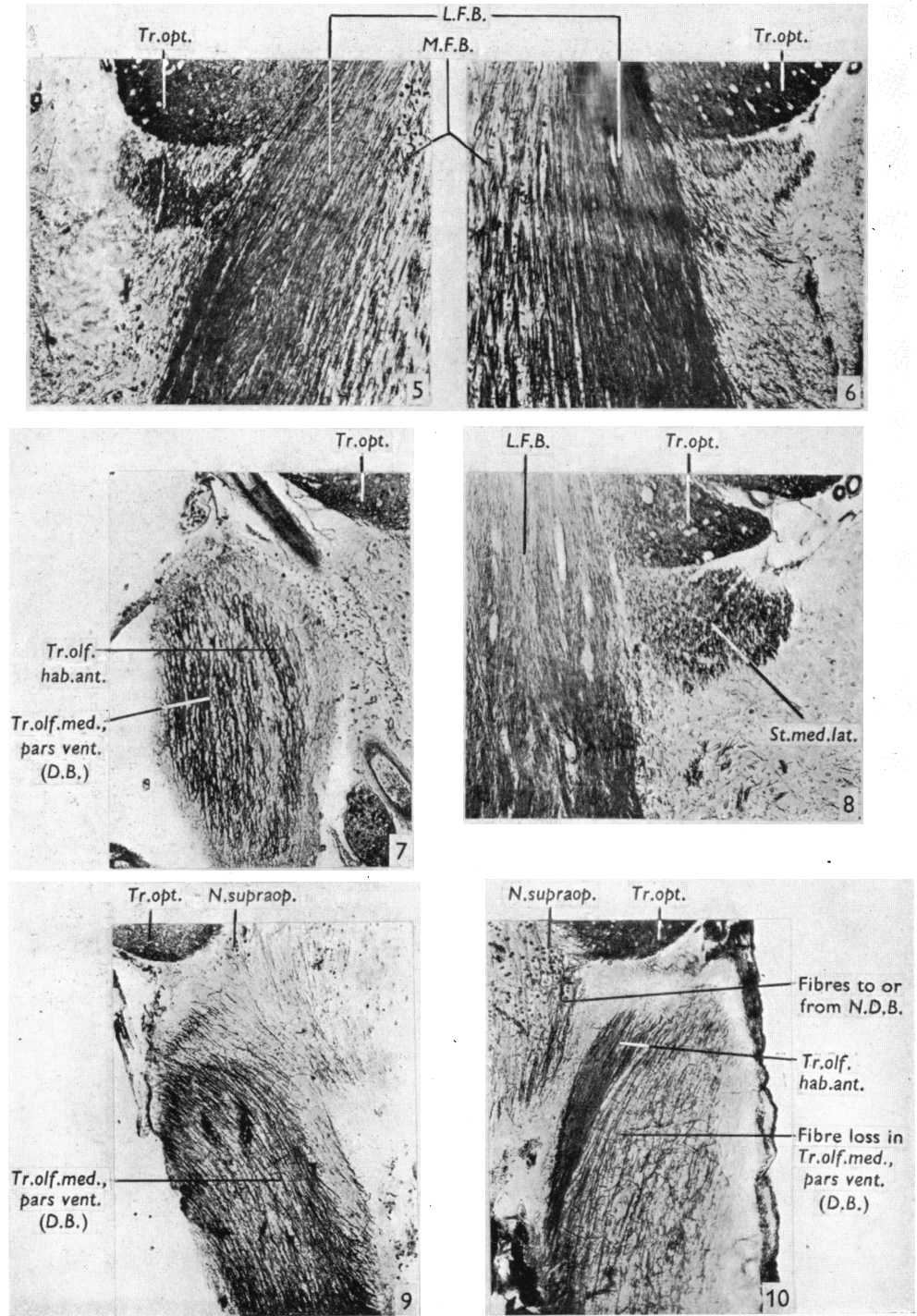
- Fig. 11. Axonal varicosities in the anterior olfacto-habenular tract 3 days after division of the habenular commissure. ( $\times 1400$ .)
- Fig. 12. Small axonal varicosities (solid and vesicular) in the superficial part of olfactory tubercle 48 hr. after removal of main and accessory olfactory bulbs (L.V. 52). Similar structures were seen throughout the superficial layer of the pyriform cortex and in the anterior olfactory nucleus in this specimen. ( $\times 1200$ .)
- Fig. 13. Axonal varicosity and two (possibly terminal) vesicular swellings in the superficial layer of the olfactory tubercle in the same specimen as in fig. 12. ( $\times 1200$ .)
- Fig. 14. Large solid axonal swellings on fibres of the ventral part of the medial olfactory tract 54 hr. after bulbar ablation (L.V. 69). These fibres are typical of those found also in the intermediate and lateral olfactory tracts in this specimen. ( $\times 1200$ .)
- Fig. 15. Low-power photograph of the region from which figs. 12 and 13 were taken, to show the extensive nature of the degenerative changes. ( $\times 450$ .)

## List of Abbreviations

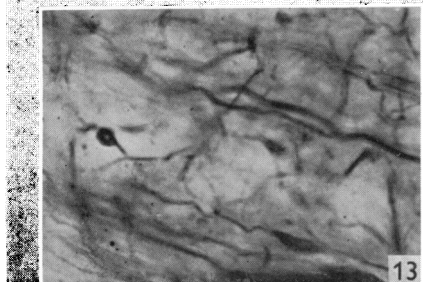
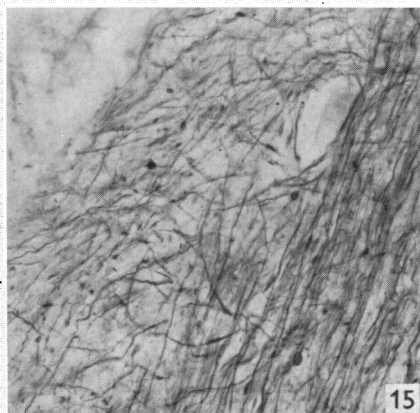
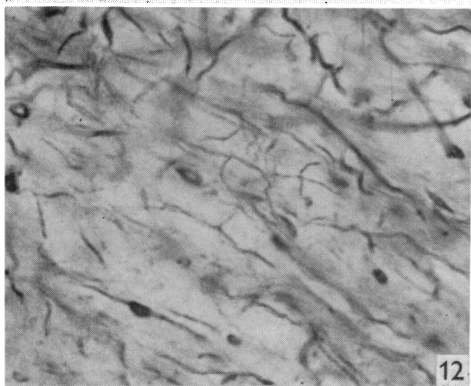
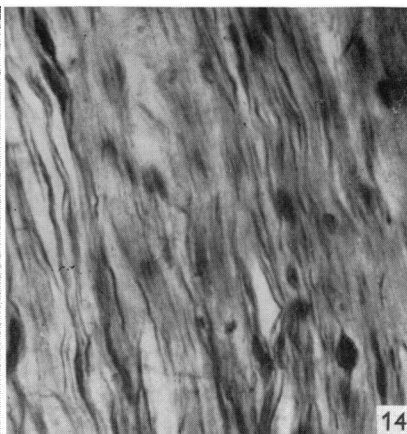
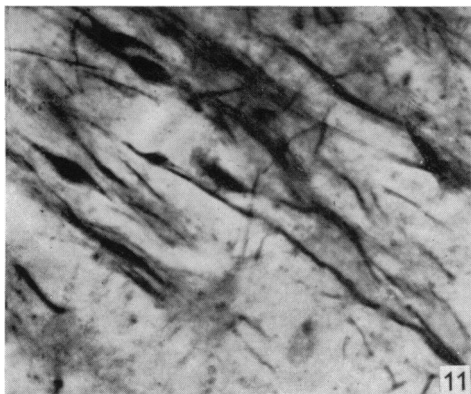
<i>D.B.</i>	Diagonal band
<i>L.F.B.</i>	Lateral forebrain bundle
<i>M.F.B.</i>	Medial forebrain bundle
<i>N.D.B.</i>	Nucleus of diagonal band
<i>N.supraop.</i>	Nucleus supraopticus
<i>St.med.lat.</i>	Stria medullaris lateralis
<i>Tr.olf.med., pars vent.</i>	Tractus olfactorius medialis, pars ventralis
<i>Tr.olf.hab.ant.</i>	Tractus olfacto-habenularis anterior
<i>Tr.opt.</i>	Tractus opticus



GAMBLE—SECONDARY OLFACATORY CONNEXIONS IN *LACERTA VIRIDIS*



GAMBLE—SECONDARY OLFACTORY CONNEXIONS IN *LACERTA VIRIDIS*



GAMBLE—SECONDARY OLFACTORY CONNEXIONS IN *LACERTA VIRIDIS*